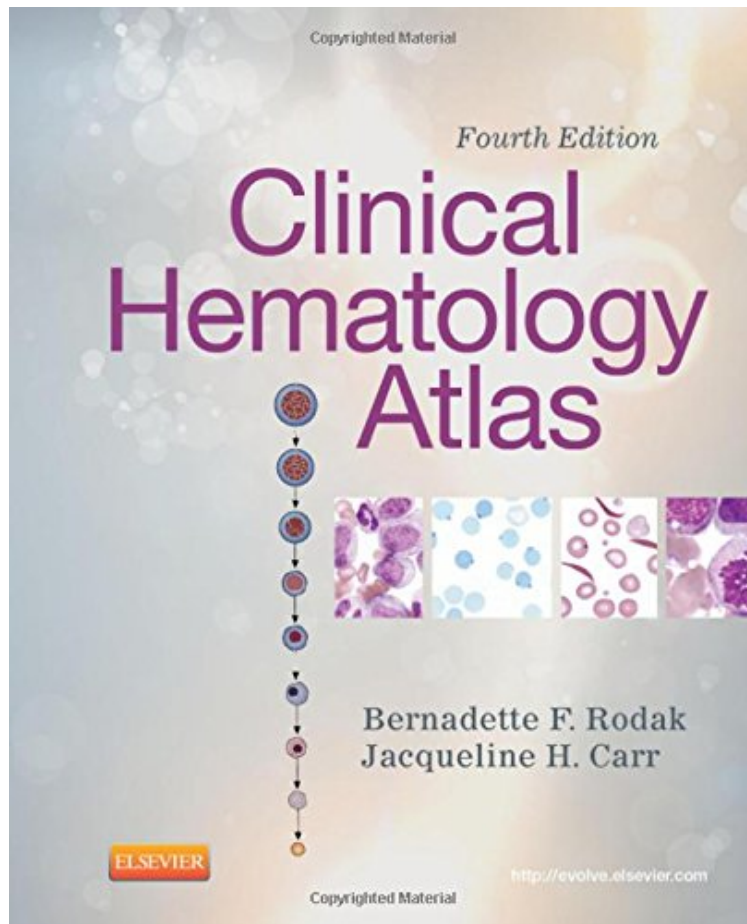


(Get free) Clinical Hematology Atlas, 4e

Clinical Hematology Atlas, 4e

Bernadette F. Rodak MS MLS, Jacqueline H. Carr MS CLSpH(NCA) CLDir(NCA)
*DOC | *audiobook | ebooks | Download PDF | ePub*



#497068 in Books 2012-04-17Original language:EnglishPDF # 1 9.50 x 8.00 x .751, 1.23 #File Name: 1455708305272 pages | File size: 55.Mb

Bernadette F. Rodak MS MLS, Jacqueline H. Carr MS CLSpH(NCA) CLDir(NCA) : Clinical Hematology Atlas, 4e before purchasing it in order to gage whether or not it would be worth my time, and all praised Clinical Hematology Atlas, 4e:

4 of 4 people found the following review helpful. Great resource for MLT students and those taking hematologyBy CustomerThis is a great resource guide for MLT students or someone taking a hematology class. I highly recommend this for any MLT or MT student or someone who is in a blood bank or hematology class.0 of 0 people found the following review helpful. HelpfulBy Kindle CustomerThis book was great for studying. The pictures are accurate. I even used this book when I first started working as a reference.0 of 0 people found the following review helpful. Fantastic, especially for pathology rotationsBy Carina DehnerFantastic, especially for pathology rotations. I was doing a lot of hematopathology and this book helped me significantly getting a grasp of what I am actually looking at.

An excellent companion to Rodak's Hematology: Clinical Principles Applications, this atlas is ideal for helping you

accurately identify cells at the microscope. It offers complete coverage of the basics of hematologic morphology, including examination of the peripheral blood smear, basic maturation of the blood cell lines, and discussions of a variety of clinical disorders. Over 400 photomicrographs, schematic diagrams, and electron micrographs visually clarify hematology from normal cell maturation to the development of various pathologies. Normal Newborn Peripheral Blood Morphology chapter covers the unique normal cells found in neonatal blood. A variety of high-quality schematic diagrams, photomicrographs, and electron micrographs visually reinforce your understanding of hematologic cellular morphology. Spiral binding and compact size make this book easy to use in a laboratory setting. Coverage of common cytochemical stains, along with a summary chart for interpretation, aids in classifying malignant and benign leukoproliferative disorders. Morphologic abnormalities are presented in chapters on erythrocytes and leukocytes, along with a schematic description of each cell, to provide correlations to various disease states. Body Fluids chapter covers the other fluids found in the body besides blood, using images from cytocentrifuged specimens. Updated information on the subtypes of chronic lymphocytic leukemia (CLL) helps you recognize variant forms of CLL you may encounter in the lab.